



EFFECT OF ROOT FRACTURE ON THE EPITHELIAL ATTACHMENT

A PRELIMINARY REPORT

C. J. DREYER AND L. BLUM*

THE treatment of fractured roots is an ever recurring problem for the practitioner. Understandably experimental evidence of the effects of fractured roots in human teeth is limited. Therefore a study of the problem was undertaken in rats. In this paper certain effects are reported.

METHOD AND MATERIALS

Wistar strain rats were chosen for the experiment and the selection of the most suitable tooth was first determined on sacrificed animals. Lack of control of mandibular movement while the fracturing force was being applied led to the choice being confined to the maxillary teeth.

Any attempt to fracture the roots of the third maxillary molar by means of specially adapted forceps tended to dislodge the entire tooth, whilst the large anterior root of the first maxillary molar resulted in bony rather than root fractures. Thus the maxillary mid-molar was chosen as the most suitable tooth for the investigation.

To produce root fractures the mid-molar of the sacrificed animal was carefully rotated until a clicking sound was heard. The maxillae were then examined radiologically and by dissection. The former method proved of little value in the determination of the presence or absence of root fractures.

The effectiveness of the technique employed as judged by dissection showed that in most cases one or more roots had been fractured without gross displacement of the tooth. The disto-buccal root was the one most frequently fractured.

This technique of fracturing the roots of the mid-molar was used for the *in vivo* experiment on 24 adult Wistar strain rats. Fourteen of the 24 animals used had to be discarded because of obvious crown damage, bony fractures or traumatized gingival tissue. Three of the remaining 10 animals selected for further study had unilateral, and seven had bilateral operations.

The experimental animals were sacrificed at intervals of one, three, 10 and 18 weeks. The maxillae were removed, fixed in formalin, decalcified in nitric acid and embedded in wax. Serial sections were cut either in the sagittal or horizontal plane and stained with haematoxylin and eosin, picro-mallory and Massons trichrome.

RESULTS

Five of the 17 specimens were sectioned in the sagittal plane and the remaining 12 in the horizontal plane. In only one of the specimens obtained from rats sectioned in the sagittal plane was there evidence of a repaired apical frac-

*Joint Council for Scientific and Industrial Research/University of the Witwatersrand Dental Research Unit, Johannesburg.

ture. One of the 12 specimens sectioned in the horizontal plane had to be discarded because of an undetected crown fracture. In the remaining 11 there were signs consistent with fracture of one or more roots. The fractures occurred at varying levels upwards from the bifurcation.

In the majority of specimens examined no pulpal tissue remained in the dislodged root fragments, while that in the coronal portion of these fractured roots showed varying degrees of cellular infiltration or necrosis. Death of the entire pulp of the affected tooth did not occur in all specimens. The pulpal tissue in the unfractured roots of some of the specimens remained viable and comparatively normal (Fig. 1).

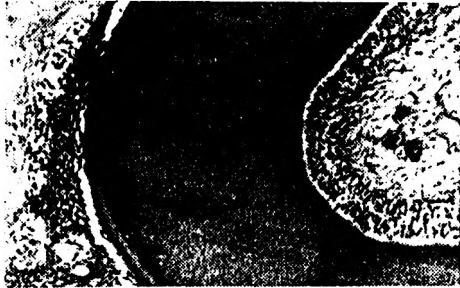


FIG. 1.—Horizontal section passing through the roots of a fractured mid-molar. This section shows the downgrowth of epithelium adjacent to a root with a viable pulp. H. and E.

The dislocated root fragments and the adjacent part of the remaining fractured root often showed signs of resorption.

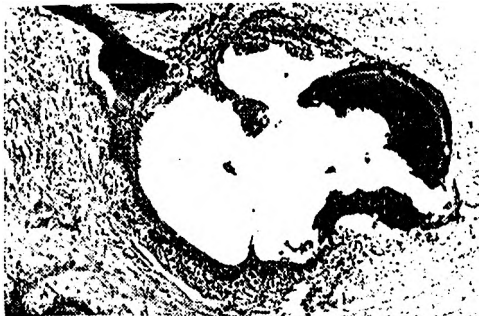

FIG. 2. Horizontal section of the maxilla passing through a fractured root of a mid-molar. The distribution of epithelium around the area occupied by the fractured root is demonstrated. H. and E.

This occurred on the pulpal cemental and fractured dentinal surfaces (Fig. 2).

The periodontal spaces around the fractured roots were enlarged; and the fibrous elements, compared with the unaffected teeth, were less dense and disorganized (Fig. 3).



FIG. 3.—Horizontal section passing through the roots of the maxillary molars. The undamaged roots seen on this section are the distal roots of the first molar. The fractured roots are the mesial roots of the mid-molar. The enlarged periodontal spaces, the disorganized fibrous elements and downgrowth of epithelium round the fractured roots is evident. H. and E.

The most striking feature in the specimens with fractured roots was the downgrowth of epithelium adjacent to the roots of the affected mid-molar. This epithelium was continuous with the crevicular epithelium and extended towards and up to the apices (Fig. 4). It usually was seen adjacent to the cemental surfaces (Fig. 1), and less frequently lining cavities containing root fragments (Fig. 2).

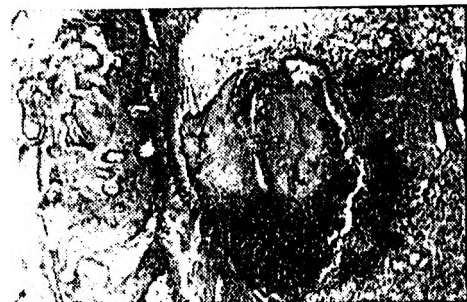

FIG. 4. Horizontal section of the maxilla passing through the apex of a root of a fractured mid-molar. This section shows a downgrowth of epithelium extending up to the apex of the root. H. and E.

The epithelial down-growths may be seen in relation to all the roots of affected teeth, but it does not encircle all of these roots completely. That associated with the unfractured roots of the affected teeth is more frequently confined to the inner root surfaces (Fig. 5). In this epithelium there was evidence of keratinization in only one of the specimens examined.

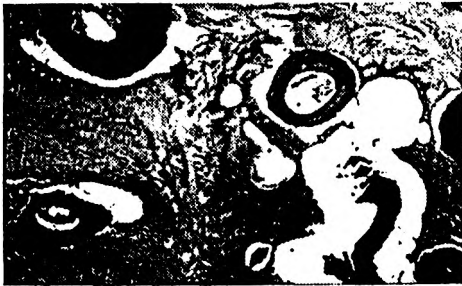

FIG. 5.—Horizontal section of the maxilla passing through the roots of a fractured mid-molar. This section shows the down-growth of epithelium on the inner surfaces of its two unfractured roots. H. and E.

DISCUSSION

If a fracture of a root is produced in the manner described its presence often can only be determined if the histological sections are cut in a favourable plane. To obtain such sections the first series of specimens were cut in the sagittal plane. Due to the divergence of the roots, their thinness and the varying thickness of cementum covering them this method proved unsatisfactory. The resultant oblique sections of these roots are difficult

to interpret. These difficulties may have contributed to the absence of fractures in the first series. Although horizontal sections also have certain disadvantages they proved to be the most satisfactory for the purpose of this investigation.

The downgrowth of epithelium was not anticipated when this experiment was started, hence no controls related to this effect were included in the experiment. The possibility of this technique of fracturing roots initiating the downgrowth of the epithelium must, however, be considered and is at present being investigated.

Postoperative examination of the periodontal tissues of the experimental animals suggests that the downgrowth of the epithelium was associated with the fracture of the roots rather than with the initial trauma to the periodontal tissues. This view is strengthened by the absence of similar effects after the construction and placement of orthodontic bands.

The epithelial downgrowth adjacent to the cementum is associated with a detachment of the fibrous elements of the periodontal ligament. Therefore a pocket or potential pocket of varying depths up to the apical region formed subsequent to root fracture.

The mechanism causing the down-growth of the epithelium and the implication that this finding has on the aetiology of some forms of chronic periodontitis will be discussed in a later paper.

ACKNOWLEDGMENTS

The authors wish to thank Dr. E. A. S. Piskorek and Mrs. L. J. Szal for their technical assistance.